



## Cardio protective effect of the semi purified flavonoids from *Musa sapientum* against isoproterenol-induced myocardial infarction in rats

J.C.M.Atiienza<sup>1</sup>, C. M. L.Baloca<sup>2</sup>, M.A.R.Bascon<sup>3</sup>, A.T.U.Calingasan<sup>4</sup>, L.A.Kadusale<sup>5</sup>,  
F.C.Cobar<sup>\*6</sup>, M.S.Andal<sup>6</sup>, C.D.Santiago<sup>6</sup>

1 College of Medicine, University of the East Ramon Magsaysay Memorial Medical Center, Quezon City, Philippines

2 Gamot Publiko, Manila City, Philippines

3 Doctor of Pharmacy, Centro Escolar University Makati Campus, Makati City, Philippines

4 Medical Center Western Batangas, BalayanBatangas, Philippines

5 Luzon Quick Serve Training Corporation, Manila City, Philippines

6 School of Pharmacy, Centro Escolar University Manila Campus, Manila City, Philippines

### ARTICLE HISTORY

Received: 22.06.2016

Accepted: 19.10.2016

Available online: 30.12.2016

### Keywords:

Cardio protection, myocardial infarction, isoproterenol, *Musa sapientum*

### \*Corresponding author:

Email : flordelyn.cobar@gmail.com

Tel.: (+63) 2 735-6861 to 71 loc. 222

### ABSTRACT

This study was designed to evaluate the cardio protective effect of the semi-purified flavonoids from banana blossoms on the basis of histopathological parameters and biochemical analysis in isoproterenol induced myocardial infarction in rats. The semi-purified flavonoids extract were used to pretreat Sprague Dawley rats for 19 days at doses 50mg/kg, 100mg/kg and 150 mg/kg. Aspirin was used as the positive control, and was given orally at a dose of 12 mg/kg. After pretreatment, two doses of isoproterenol (85mg/kg body weight per dose, subcutaneously) were injected to rats at an interval of 24 hours for two days (20th and 21st day) to induce myocardial infarction. Twenty-four hours after the last dose of isoproterenol, all rats were sacrificed via cervical dislocation. In comparison with the negative and positive control, results showed that at doses 100mg/kg and 150mg/kg, the semi-purified flavonoids extract did not exhibit cardio protection. At 50mg/kg, the semi-purified flavonoids extract exhibited cardio protection comparable to that of Aspirin hence indicating that the semi-purified flavonoids from banana blossom has a cardioprotective effect against isoproterenol-induced myocardial infarction in rats.

### INTRODUCTION

The heart is one of the most important organs in the entire human body. It pumps the blood, that carries all the vital materials which help our body's function and removes the waste products that we do not need. The brain requires oxygen and glucose, which, if not received continuously, will cause it to lose consciousness. Muscles need oxygen, glucose and amino acids, as well as the proper ratio of sodium, calcium and potassium salts in order to contract normally. The glands need sufficient supplies of raw materials from which to manufacture the specific secretions. If the heart ever ceases to pump blood the body begins to shut down and after a very short period of time, will die.

As marvelous as this system is, it is very vulnerable to damage from the things we do to it, like smoking, eating an unhealthy diet or putting it under stress. Or you may be born with a heart condition. When the heart's functions become compromised, this is known as cardiovascular disease [1].

Cardiovascular diseases accounts for one of every three deaths in America, and claims for 17.1 million lives a year, projecting it as the number 1 cause of death over AIDS and all forms of cancer combined. It is a broad term that covers any disorder to the system that has the heart at its center. It includes coronary heart disease (heart attacks), cerebrovascular disease (stroke), elevated blood pressure (hypertension), peripheral artery disease, rheumatic heart disease, congenital heart disease and heart failure [2].

A heart attack, also called myocardial infarction, or MI, is usually triggered by the rupture of a plaque within a coronary artery. This plaque rupture causes a blood clot (or thrombus) to form, leading to blockage of the artery. The portion of the heart muscle being supplied by the blocked artery then begins to die - and the death of heart muscle is what defines a myocardial infarction [3].

With this problem, various cardiac therapies one of the most effective being aspirin have led to substantial improvements in

the management of coronary heart disease. Aspirin is an inexpensive, well-tolerated platelet inhibitor that has proven benefit in the secondary prevention of AMI, unstable angina, stroke, and all-cause and cardiovascular-associated mortality [4]. At the time of having a heart attack, a big part of the problem is the growth of the blood clot within the affected artery. Formation of this blood clot depends on the blood platelets, which are tiny blood cells whose job is to participate in blood clotting. It turns out that aspirin - in small doses - can rapidly and powerfully inhibit the activity of the platelets, and therefore can inhibit the growth of the blood clot. Inhibiting the growth of the blood clot is critical if you're having an MI, since maintaining at least some blood flow through the coronary artery can prevent heart muscle cells from dying [5]. However, although aspirin is an effective, inexpensive, and safe treatment of acute myocardial infarction, the frequency of use of aspirin entails dealing with its side effect (ie increased risk of bleeding) and contraindications such as hypersensitivity to aspirin, active peptic ulcer, hemophilia, treatment with warfarin or other anticoagulants and other bleeding disorders [5].

These unwanted effects lead to the discovery of natural means of addressing such problems. The plant kingdom is a large reservoir of unexplored biologically active compounds like phytochemicals, which are suggested to be the major bioactive compounds contributing to the health benefits of fruits and vegetables [6]. Among these are flavonoids which can be found in the Musaceae family, and have been proven to have antioxidant, anti-ulcer, anti-inflammatory, anti-microbial and anti-convulsant activities, among others [7].

Banana Blossoms, which contains flavonoids, have long been utilized as vegetable [7]. Apart from this, it has also been stated to be effective against conditions ranging from the inflammatory to several serious disorders namely hyperlipidemia, arthritis, cancer and notably, heart diseases [8].

This study was conducted to evaluate the cardio protective effect of the semi-purified flavonoids from banana blossom on isoproterenol induced myocardial infarction in rats. Specifically, it sought to extract and purify the flavonoids present in banana blossom, to identify the concentration of the flavonoids extract which exhibits cardioprotective effect, and to compare the extent of cardio protection of the flavonoids extract with that of the positive control.

## MATERIALS AND METHODS

### Chemicals

All chemicals used in the study were obtained from the CEU Physical Sciences Department, except for Isoproterenol Hydrochloride, which was purchased from Chemline Scientific Corporation and Aspirin, which was purchased from Mercury Drug Corporation.

### Plant Material

Banana blossoms were collected from the Nepa Q Mart (harvested from Catanauan, Quezon) during the months of July to August 2014. The samples were duly authenticated by the Botany Division of the National Museum. The banana blossom were peeled and cut into small pieces using a blender prior to extraction.

### Extraction

Pulverized Banana blossom were macerated with hot

methanol for 48 hours. The methanol extract was filtered and was then evaporated to incipient dryness. The residue was further re-extracted with diethyl ether and ethyl acetate to obtain the flavonoids.

### Instrumental Analysis for the identification of Flavonoids

Fourier Transform Infrared Spectroscopy (FTIR)-PERKINS™ and High Performance Liquid Chromatography (HPLC)-AGILENT™ were used for further identification of the extracted flavonoids. The tests were done at De La Salle University Manila Chemistry Laboratory Department. In FTIR, the results were referred to the Infrared Spectroscopy Correlation Table to identify the functional groups present in the extract. In HPLC, the results from the standard were compared to the results of the extract to determine the specific flavonoids present.

### Animals

Fifteen (15) Sprague-Dawley rats weighing 150-200 grams were purchased from Department of Science and Technology. The rats were housed in the CEU Animal Facility in a 12"x 16"x7" (LxWxH) plastic cage with wood shavings as bedding. The CEU Animal Facility is an air conditioned room, and laboratory animals are placed under 12h dark/12h light condition.

The rats were acclimatized for one week prior to the start of the biological test. Cleaning was done every 2 days using soap, rinsing with water, disinfecting with 10% sodium hypochlorite and then properly drying. During the experimental period, the rats were fed with a normal diet and water *ad libitum*.

All animal experiments were performed with prior approval from the Institutional Animal Care and Use Committee (IACUC) of Centro Escolar University.

### Animal Treatment Model

The rats were divided into five groups, with three rats each: (I) Negative Control, (II) Positive Control, (III, IV, V) Experimental Groups - pretreated with semi-purified flavonoids extract. The biological test was done for a period of 21 days.

Group I: Normal diet for 19 days + isoproterenol (85mg/kg) on 20<sup>th</sup> and 21<sup>st</sup> day

Group II: Aspirin pretreatment (12mg/kg) for 19 days + isoproterenol (85mg/kg) on 20<sup>th</sup> and 21<sup>st</sup> day

Group III: Semi-purified flavonoids extract pretreatment (50mg/kg) for 19 days + isoproterenol (85mg/kg) on 20<sup>th</sup> and 21<sup>st</sup> day

Group IV: Semi-purified flavonoids extract pretreatment (100mg/kg) for 19 days + isoproterenol (85mg/kg) on 20<sup>th</sup> and 21<sup>st</sup> day

Group V: Semi-purified flavonoids extract pretreatment (150mg/kg) for 19 days + isoproterenol (85mg/kg) on 20<sup>th</sup> and 21<sup>st</sup> day

### Histopathological study

At the end of the study, all the rats were sacrificed by cervical dislocation and the hearts were dissected out. The myocardial tissue was immediately fixed in 10% buffered formalin solution. After fixation, tissues were embedded in paraffin. Five micrometer thick sections were cut and each section was stained with hematoxylin and eosin. The slides were examined under

light microscope and photographs were taken.

### Biochemical Analysis of the blood serum

About 2ml of blood samples were collected via intracardiac extraction and were centrifuged at 2000 rpm for 10 minutes for the separation of serum. The separated serum was analyzed for serum markers enzymes lactate dehydrogenase (LDH) and Creatine kinase-MB (CK-MB).

### Statistical Treatment

Statistical analysis of the Histopathological Study will be performed by One-way ANOVA followed by Dunnett's test to compare the diseased and treated groups, and Fisher's LSD test to compare between each groups in terms of heart damage. Biochemical analysis of the blood serum will be done using Two-Tailed t-Test to compare the CKMB and LDH level difference

between the pre-test and post-test. The results would be considered statistically significant, if  $p < 0.05$ .

### RESULTS

The percentage yield of the banana blossom extract was 17.93%. Results of the physical, chemical and instrumental tests all confirmed the presence of flavonoids.

### Determination of the Functional Groups Present in the semi-purified Flavonoids Extract by Fourier Transform Infrared Spectroscopy (FTIR)

Fourier Transform Infrared Spectroscopy (FTIR)-PERKINS™ was used for further identification of the flavonoids. Figure 1 shows the infrared spectra of the flavonoids extract.

The results showed that it has strong, broad phenolic

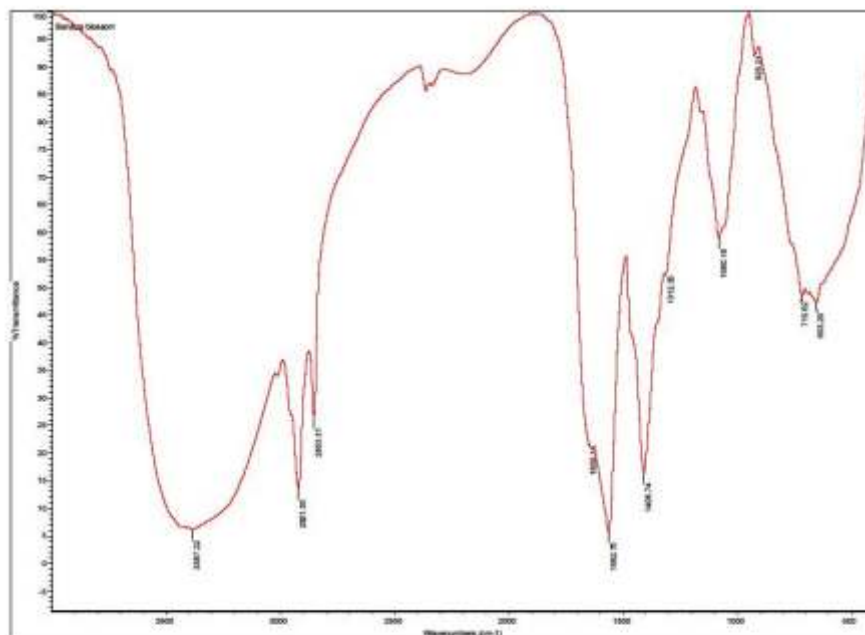
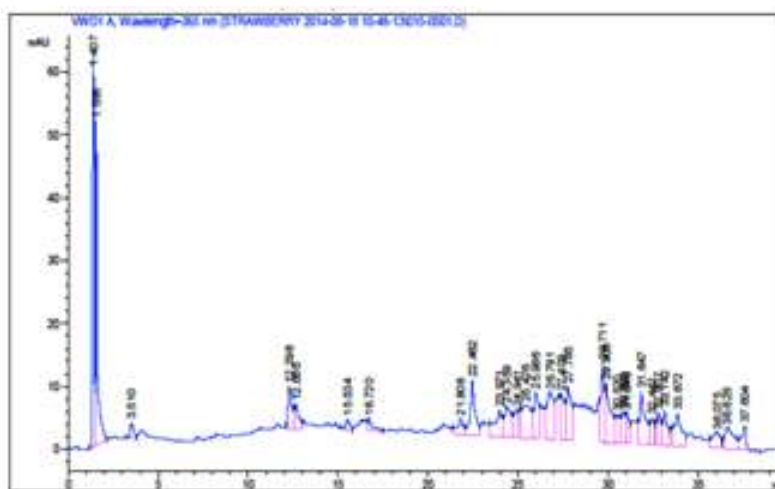


Fig 1 : Infrared Spectra of the Flavonoids Extract



functional group, as well as weak to strong aromatic carbons, a characteristic common to flavonoids.

### Determination of the Specific Flavonoids Present in the Banana blossom Extract by High-Performance Liquid Chromatography (HPLC)

High-Performance Liquid Chromatography (HPLC)-AGILENT™ was used for determining the specific flavonoids present in the extract. The test was done at De La Salle University Manila Chemistry Department.

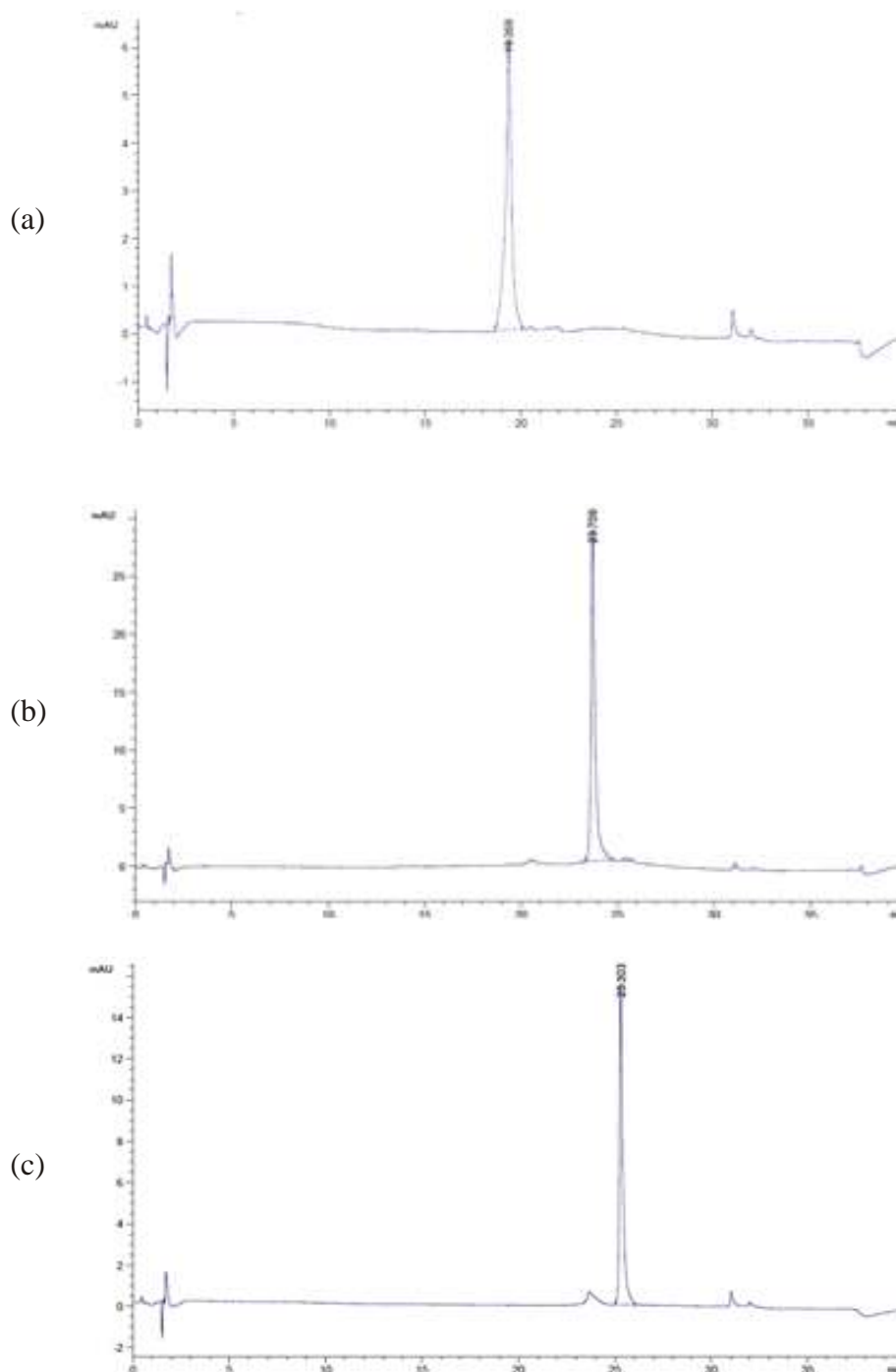
Figure 2 shows the result of HPLC on the flavonoids extract. Retention time (min) of Rutin, Quercetin and Kaempferol in the

flavonoids extract of *Musa sapientum* are 19.598, 23.947 and 25.304, respectively.

Figure 3 shows chromatogram of the standard solution used. Retention time (min) of the standards Rutin, Quercetin and Kaempferol are 19.369, 23.709 and 25.303, respectively. The results showed that the banana blossom extract contains Kaempferol, Quercetin and Rutin since their retention time values were closely the same with that of the standards used.

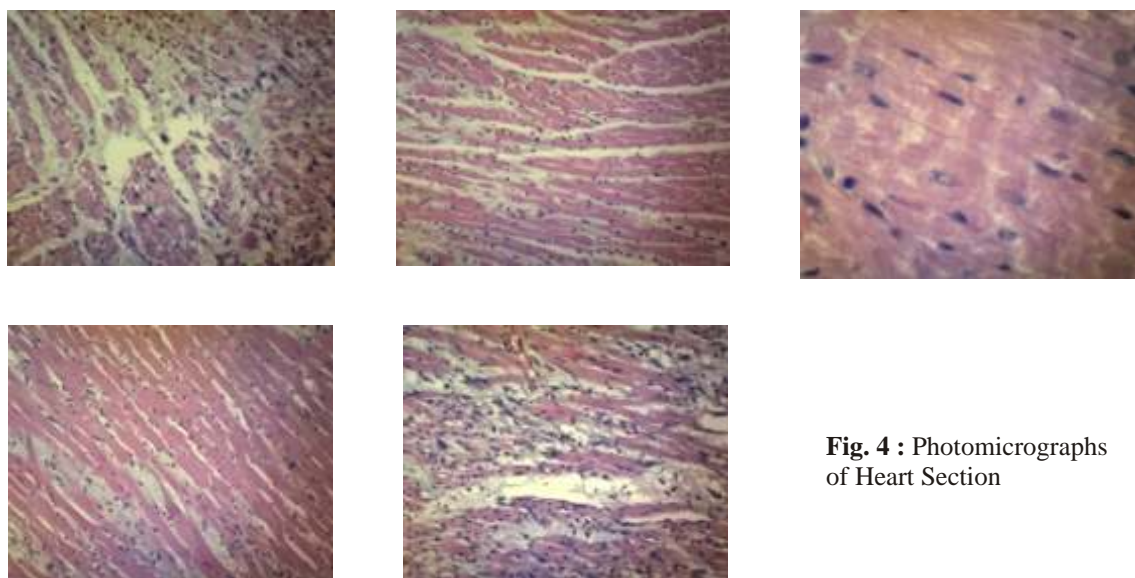
### Histopathological Findings

Photomicrographs of heart section were shown in Figure 4.



**Fig 3.** : Chromatogram of Rutin, Quercetin and Kaempferol Standard  
Chromatogram of the Standards (a) Rutin (b) Quercetin (c) Kaempferol





**Fig. 4 :** Photomicrographs of Heart Section

Photomicrographs of heart sections stained with hematoxylin and eosin. (a) Group I showing heart tissue damage indicative of MI. (b) Group II showing cardioprotection exhibited by aspirin. (c) Group III showing less heart tissue damage (d) Group IV showing heart tissue damage indicative of MI (e) Group V showing heart tissue damage indicative of MI.

Photomicrographs of the hearts from the negative control group had focal areas showing presence of contraction bands in cardiomyocytes, mild to moderate necrosis of cardiomyocytes and moderate to severe loss of cross striations of cardiomyocytes, suggestive of myocardial infarction. However, both Group II and III showed no contraction bands observed in cardiomyocytes but mild necrosis, mild to moderate necrosis and mild loss of cross striations were observed. Photomicrographs of the heart from Group IV showed moderate to severe myocardial necrosis and moderate to severe loss of cross striations of cardiomyocytes. For Group V, moderate to severe myocardial necrosis, severe myocardial necrosis and mild to moderate presence of contraction bands were observed.

## DISCUSSION

Comparison between the Banana Blossom Flavonoid Extract and the Negative Control. The results of the histopathological study from the negative control group showed the structure of a severely damaged heart manifested by the presence of contraction bands and mild to moderate necrosis in cardiomyocytes, mild to moderate necrosis of cardiomyocytes and moderate to severe loss of cross striations of cardiomyocytes, suggestive of myocardial infarction. The cardioprotection from myocardial infarction was confirmed from the photomicrographs and findings of the hearts from Group II since there were no contraction bands observed in cardiomyocytes, mild necrosis, mild to moderate necrosis, as well as mild loss of cross striations.

The results of the histopathological study of the hearts from the experimental rats (Groups III, IV and V) were compared to that of the results from the negative and positive control, in order to identify the effect of the flavonoids extract from Banana Blossom.

Groups IV and V, which were pre-treated with the semi-purified flavonoids extract at a dose of 100 and 150 mg/kg

respectively, were found to be ineffective in protecting the heart from myocardial necrosis, resulting from the administration of isoproterenol. This was evident in the extent of the damage, as seen in the photomicrographs of the heart from the said groups. Results of the histopathological study of the hearts from Group III, which were administered with 50 mg/kg of the semi-purified flavonoids extract showed that at this lower dose, the semi-purified flavonoids extract was able to protect the heart from myocardial damage, evidenced by the absence of contraction bands and a few necrotic cardiomyocytes observed. Mild loss of cross striations in the cardiomyocytes was also found to be discernible.

Dunnett's test treated one group as a control, and compared all other groups against it. The mean difference was significant at the 0.05 level. The results showed that Group III has a P-value of 0.000 hence rendering significant difference when compared to the negative control. On the other hand, Groups IV and V had no significant difference since they had a P-value of 0.885 and 1.000, when compared to the negative control.

Fisher's LSD test shows the comparison between each group in terms of Heart Damage. The mean difference was significant at the 0.05 level. Results showed that when the positive control was compared with groups III, IV and V, their significant value were 0.631, 0.002, and 0.001, respectively. When group III was compared with the positive control, group IV and V, their significant value were 0.631, 0.004, and 0.002, respectively. When Group IV was compared with the positive control, group III and V, their significant value were 0.002, 0.004 and 0.631, respectively and when group V was compared with the positive control, group III and V, their significant value were 0.001, 0.002 and 0.631, respectively.

Using Dunnett's and Fisher's LSD test method as the descriptive statistical treatment for the histopathological study, results showed that Group II and III had significant difference when compared to the negative control group, indicating cardioprotection. However, Group IV and V did not have any significant difference to that of Group I, indicating the absence of cardioprotection.

Comparison between the Banana blossom semi-purified

flavonoids extract and the Positive Control. The photomicrographs obtained from the positive control group (Group II) which were administered with Aspirin (12mg/kg) and the experimental groups (Groups III, IV, and V) were compared to determine if the semi-purified flavonoids extract, at doses 50, 100 and 150 mg/kg has a cardio protective effect comparable to that of aspirin.

At doses 100 mg/kg and 150 mg/kg, the semi-purified flavonoids extract did not exhibit any cardio protective effect since the results of the histopathological study showed that there was myocardial necrosis, contraction bands and absence of cross striations which were suggestive of myocardial infarction. At the lowest dose, which was 50 mg/kg, results showed that the extract was comparable to the positive control, aspirin. This was evident in the interpretations provided. Hearts of aspirin pre-treated rats showed no contraction bands in cardiomyocytes, mild necrosis and mild loss of cross striations. Likewise, hearts of semi-purified flavonoids extract pretreated rats at a dose of 50 mg/kg showed no contraction bands in cardiomyocytes, mild, mild to moderate necrotic cardiomyocytes and mild loss of cross striations suggesting the cardio protection provided by the extract as compared to that of aspirin.

Dose 50 mg/kg (Group III) showed no significant difference to that of Group II. Group III had a P-value of 0.885 which was greater than and has significant difference to the 0.05 level. However, Group IV (100mg/kg) and Group V (150 mg/kg) had significant difference to the P-value of Group II since they both had a P-value of 0.000 showing significant difference to the 0.05 level.

Using the Dunnett's test method as the descriptive statistical treatment for the histopathological study, results showed that only Group III showed no significant difference when compared to the positive control making it comparable to the effectiveness of Aspirin against myocardial infarction.

Biochemical analysis of the blood serum showed that the CKMB and LDH level of Groups II and III do not have significant difference after the pre-test and post-test, indicating cardioprotection. Group II has a P-value of 0.367 and 0.462 for CKMB and LDH, respectively, while Group III has a P-value of 0.621 and 0.403 for CKMB and LDH, respectively. However, Groups IV and V, showed significant difference on the CKMB and LDH level after the pre-test and post-test, indicating heart damage. Group IV has a P-value of 0.014 and 0.003 for CKMB and LDH, respectively, while Group V has a P-value of 0.009 and 0.002 for CKMB and LDH, respectively.

It indicated that only Group III (50mg/kg dose) showed comparable cardioprotection to that of the Aspirin since it had no significant difference when compared to Group II's (positive control) CKMB and LDH level during the pre-test and post-test. On the other hand, Groups IV and V were ineffective in providing cardioprotection since, they have showed significant difference on CKMB and LDH level during the pre-test and post-test when compared to the positive control.

## CONCLUSION

Based on the data obtained, the researchers conclude that at dose 50mg/kg, the semi-purified flavonoids from Banana Blossom was comparable to the cardio protection exhibited by Aspirin against Isoproterenol-induced Myocardial Infarction.

## REFERENCES

1. Murphy, M.P., Hohl, C., Brierley, G.P., & Atschul, R.A. Release of Enzymes from Adult Rat Heart Myocytes" *Journal of the American Heart Association*, 51, 560-568, doi: 10.1161/01.RES.51.5.560. 1982
2. Evans, William C. Trease and Evans' *Pharmacognosy* (16<sup>th</sup> ed.). Singapore: Saunders Elsevier. 2010.
3. World Heart Federation. Available at <http://www.world-heart-federation.org/cardiovascular-health/cardiovascular-disease-risk-factors/>. 2015.
4. World Health Organization. Available at [http://www.who.int/topics/cardiovascular\\_diseases/en/](http://www.who.int/topics/cardiovascular_diseases/en/). 2015
5. Cardiovascular diseases. Available at [http://www.who.int/topics/cardiovascular\\_diseases/en/](http://www.who.int/topics/cardiovascular_diseases/en/). 2015
6. Myocardial Infarction. Available at <http://emedicine.medscape.com/article/155919-overview>. 2014
7. Saging. Available at <http://www.stuartxchange.com/Saging.html>. 2015
8. Bilton, P. Banana Flower or Banana Blossom: Culinary Uses and Nutritional Value. Available at <http://foodnutrition.knoji.com/banana-flowers-or-banana-blossom-culinary-uses-and-nutritional-value/>. 2009